



УДК 569.614: 551.792(470.63)

## ABOUT CASES OF PATHOLOGY OF THE DENTAL SYSTEM IN *ARCHIDISKODON MERIDIONALIS MERIDIONALIS* (NESTI, 1825) FROM GEORGIEVSK SAND PIT (STAVROPOL TERRITORY, RUSSIA)

A.K. Shvyreva<sup>1</sup> and V.V. Titov<sup>2\*</sup>

<sup>1</sup>Stavropol State Historical, Cultural and Natural-Landscape Museum-Reserve named after G.N. Prozritelev and G.K. Prave, Dzerzhinsky Str. 135, 355035 Stavropol Territory, Stavropol, Russia; e-mail: annashvyreva@mail.ru;

<sup>2</sup>Southern Scientific Center of the Russian Academy of Sciences, Chekhov Str. 41, 344006 Rostov-on-Don, Russia; e-mail: vvtitov@yandex.ru

### ABSTRACT

Two cases of the dental system's dysfunction in *Archidiskodon meridionalis meridionalis* found in the Georgievsk sand pit (Stavropol Territory, Russia; Early Pleistocene, Psekups Faunal complex) are described. One of the tusks is missing in one of the elephant's skull, and its alveolus is overgrown. Probably, the tusk was broken off already in the alveolus at the adult animal, after which its growth process did not renew. On the skull from a skeleton of the second animal on the left upper jaw there is a disturbance of the M2 teeth change on M3 teeth. Tooth M2 is somewhat displaced lingually because of its falling delay. The anterior part of tooth M3 is beveled buccally relatively to the axis of the crown approximately at 104°. At the same time, the medial half of the first six enamel plates were significantly turned out laterally. On the other teeth noticeable changes were not noted. An obvious cause of this anomaly was a disruption of M3 growth rate and slowing of the rate of crown wearing and resorption of two posterior roots of M2. The described pathology was probably not a consequence of genetic predispositions, infection, or trauma. There are signs of osteodystrophy at separate bones of the skeleton.

**Key words:** Early Pleistocene, meridionaloid elephant, molar, Stavropol Territory, tooth pathology, tusk

## О СЛУЧАЯХ ПАТОЛОГИИ ЗУБНОЙ СИСТЕМЫ У *ARCHIDISKODON MERIDIONALIS MERIDIONALIS* (NESTI, 1825) ИЗ ГЕОРГИЕВСКОГО КАРЬЕРА (СТАВРОПОЛЬСКИЙ КРАЙ, РОССИЯ)

A.K. Швырева<sup>1</sup>, В.В. Титов<sup>2\*</sup>

<sup>1</sup>Ставропольский государственный историко-культурный и природно-ландшафтный музей-заповедник имени Г.Н. Прозрителева и Г.К. Пправе, ул. Дзержинского 135, 355035 Ставропольский край, Ставрополь, Россия; e-mail: annashvyreva@mail.ru;

<sup>2</sup>Южный научный центр РАН, пр. Чехова 41, 344006 Ростов-на-Дону, Россия; e-mail: vvtitov@yandex.ru

### РЕЗЮМЕ

Описано два случая нарушения функционирования зубной системы у *Archidiskodon meridionalis meridionalis*, найденных в Георгиевском песчаном карьере (Ставропольский край, Россия; ранний плейстоцен, псекупский фаунистический комплекс). На одном из черепов слона отсутствует один из бивней, а его альвеолярный карман зарос. Вероятно, бивень был обломан в альвеоле уже у взрослого животного, после чего процесс роста не возобновился. На черепе от скелета второго животного на левой верхней челюсти наблюдается нарушение смены зубов М2 на М3. Из-за задержки выпадения зуб М2 несколько смещён лингвально. Передняя часть

\*Corresponding author / Автор-корреспондент

зуба М3 оказалась скошенной буккально по отношению к оси коронки примерно на 104°. При этом медиальная половина первых шести эмалевых пластин оказалась значительно завёрнутой латерально. На остальных зубах заметных изменений не отмечено. Явной причиной данной аномалии стало нарушение скорости роста М3 и замедление скорости стирания коронки и резорбции двух задних корней М2. Описанная патология, вероятно, не является следствием генетических предрасположенностей, инфекционного воздействия или травмы. На отдельных костях скелета присутствуют признаки остеодистрофии.

**Ключевые слова:** ранний плейстоцен, меридионалоидный слон, моляр, Ставрополье, зубная патология, бивень

## INTRODUCTION

At the moment there are a number of publications on pathologies of the dental system of fossil elephants. However, most of them concern the teeth of a woolly mammoth *Mammuthus primigenius* Blumenbach, 1799 (Vereshchagin 1960, 2002; Lister and Bahn 2007, etc.). Some cases of mammoth tusks' disturbances of anlagen and formation and their injuries were described (Vereshchagin 1960; Lister and Bahn 2007; Maschenko et al. 2008; Nikolaev et al. 2017). Several variations of the cheek teeth abnormality of *M. primigenius* are known: the changes that have arisen during the forming of the tooth, the formation of separate elements (plates), and the functioning of the teeth (Kirillova 2009). Most often, such derangements are noted on teeth of M2–M3 generations. Cases of displacement of the tooth crowns' axis relatively to the alveolar line during the replacement are often. They are caused by a disorder of the growth rate of the subsequent tooth and the erasure rate of the previous one (Garutt 1977). With a slight mutual shift of the crowns (for example, as in the case of the mammoth from Kastykhtakh (Yakutia)), this situation had little effect on the condition of the animal which still feeds normally (Kirillova et al. 2012). In the case of a significant displacement of the teeth relatively to each other, the horizontal branch of the mandible expanded (Adam 1994; Lister and Bahn 2007) and/or the deformation of the crown of the subsequent tooth happened. In the second case, the crown of the tooth could be located across the lower jaw (as on the lower jaw of Kostenki I, Kuzmina and Praslov 1992) or even vertically (the tooth from Yakutia, Vereshchagin 1960). But cases of displacement of anterior or posterior parts of the M3/m3 crown relative to each other are more often (Wojtal 2001; Maschenko and Shpansky 2005; Krzemińska 2008; Kirillova 2009; Shpansky 2014). The degree

of crown's curvature could vary from bending or complete displacement of the back plates to the side surface of the tooth to a significant fan-like twisting of the tooth axis (for example, as in the case of M3 from Tomsk, Maschenko and Shpansky 2005). These cases were accompanied by indisposition of animals, and sometimes were the cause of their death. Examples of odontomas and supplemental teeth M4/m4 were described also (van Essen 2004; Lister and Bahn 2007; Maschenko et al. 2008). Various abnormalities of dental cement damage (Niven and Wojtal 2002, 2003; Krzemińska 2008; Kirillova 2009) and the fusion of two successive replacements (Burns et al. 2003) have been noted, too.

Teeth of *Mammuthus trogontherii* (Pohlig, 1885) with the abnormal surface abrasion abnormalities (Foronova 1999) and an additional supplemental tooth M4/m4 (van Essen 2004) are also known. Similar pathologies are observed in modern elephant species, too (Roth 1989; Colyer 1994).

Information on disturbance of the dental system in meridionaloid elephants is much less. On the skull of the whole skeleton *Mammuthus* (= *Archidiskodon*) *meridionalis vestinus* Azzaroli, 1972 from Scoppito (Italy), exposed in the Paleontological Museum of the Abruzzo Castle in the vicinity of Aquila town (Rossi et al. 2017), one of the tusks is missing. During the restoration of the exposition, partially damaged during the 2006 earthquake, traces of a wound in the area of the alveoli of the absent left tusk were found. It was concluded that the loss of the tusk was happened due to a lifetime injury.

On the skull of the elephant *Archidiskodon meridionalis tamanensis* Dubrovo, 1964 from Nogaysk (Obitchnoe, Primorsk, Ukraine, coll. ZIN No. 4318) during life was broken off at 89 cm from the edge of the alveoli (Garutt 1954). Unevenness pressure on the chewing teeth as a result of a significant difference in the weight of the whole and damaged

tusks led to an unnatural erosion of the masticatory surfaces M3/m3, which turned out to be oblique in the buccal-lingual direction (V.S. Baygusheva, pers. comm. 2017).

There are some cases of the presence of additional premolars together with molars at *Protelephas planifrons* (Falconer et Cautley, 1846), *Elephas celebensis* Hoojer, 1949, *A. meridionalis*, *Mammuthus imperator* (Leidy, 1858), *M. trogontherii* and “*Protelephas proplanifrons*” (Osborn, 1934) (Gromov 1977; Dubrovo 1989; Aguirre and Morales 1990; Baygusheva et al. 2016). For example, the simultaneous functioning of dP2 and M1 is known on the skull of the *A. m. gromovi* from Khapry (coll. GIN, No. 300/122), interpreted as atavism (Dubrovo 1989), a disorder of the development of dP2 (Maschenko 2002) or a rudiment (Titov 2008).

There are separate tooth finds with additional enamel columns and displaced plates in the serial collections of meridionaloid elephants from the territory of the south of European Russia (*A. meridionalis gromovi* from Liventsovka (Rostov Province) and Sablyia (Stavropol Territory), *A. meridionalis tamanensis* from Sinaya Balka/Bogatyri (Krasnodar Territory)). And, usually, such lumps are located on the lingual surface of the crown of the upper teeth (Figs. 1, 2), and on the buccal – on the lower ones. Intercalary plates in the form of 1–2 enamel columns, reaching the middle of the masticatory surface, are also common. Such structure often occurs not only in the middle, but also in the anterior, less often in posterior parts of the crown (regardless of its curvature). There are some samples with abnormal wearing of the tooth in the form of smoothed surface or weak buccal-lingual chewing of the masticatory surface.

The anomalies in the development of the dental system of southern elephants *Archidiskodon meridionalis meridionalis* (Nesti, 1825) from sand and gravel quarries, which were located at 5 kilometers north-west of the city of Georgievsk, near the Alexandryiskaya village, on the right side of the valley of the Kuma River, are described in this report (Garutt and Safronov 1965; Lebedeva 1978; Garutt 1998). The age of the fossiliferous deposits is defined as the pre-Absheronian (Tesakov 2004). The fauna of large and small mammals from the layers of this locality refers to the end of the Villanian, the end of the zone MNQ 17, the beginning of the Late Villafranchian, and the beginning of the Psekups theriocomplex (Titov and Shvyreva 2016). Nowadays these sand

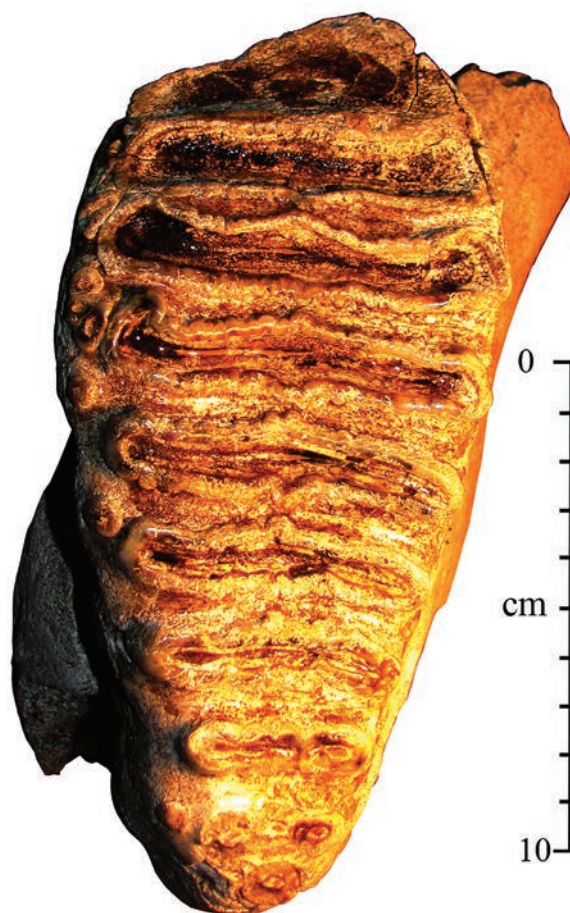

Fig. 1. Occlusal surface of the left upper tooth M3 of *Archidiskodon meridionalis gromovi* from the locality of Sablya (collection SGMZ No. 19977), Stavropol Territory; Early Pleistocene, Middle Villafranchian.




Fig. 2. Lingual view of the right upper tooth M3 of *Archidiskodon meridionalis gromovi* from the Liventsovka sand pit (collection AMZ No. KP 27212/316), Rostov Province; Early Pleistocene, Middle Villafranchian.





**Fig. 3.** A group of employees of the Zoological Institute of the Academy of Sciences of the USSR and the Stavropol Regional Museum mounted the skull of *Archidiskodon meridionalis meridionalis* (collection PKM No. OF 4622) from Georgievsk sand pit in Pyatigorsk. From left to right: A.A. Kolokolchikov (sculptor), I.P. Zorina, V.E. Garutt, I.N. Khitrov (sculptor), A.K. Shvyreva (1965).

pits are reclaimed. The first in Stavropol Territory almost complete skeleton of the southern elephant *A. meridionalis meridionalis* (coll. SGMZ) was found in 1960 in Georgievskiy sand pit. It was mounted after restoration in the Stavropol Museum of Local History in 1962. In 1964, two more skulls of this species were excavated in the same sand pit (coll. PKM, ZIN). From there the finding of the lower jaw of a young elephant with teeth dp3-dp4 (coll SGMZ) is also known, as well as isolated postcranial bones of elephants.

Excavations, restoration and mounting of skulls and the skeleton of elephants from the Georgievskiy sand pit took place under the guidance and with the direct participation of the senior scientific employee of the Zoological Institute of the USSR Academy of Sciences Vadim Garutt (Fig. 3). He trained beginner paleontologists to work with fossil material not only

in the laboratory, but also in the field. Vadim Evgenovich generously shared with them his knowledges and experience. Many of them took a ticket to the world of science. We, his followers, with gratitude honor the memory of our teacher and outstanding scientist.

## MATERIAL AND METHODS


Skull of *A. meridionalis meridionalis* (coll. PKM No. OF 4622), Georgievskiy sand pit, 1964 excavations. Teeth M2/m2 – M3/m3 from the skull of the mounted skeleton of *A. meridionalis meridionalis* (coll. SGMZ No. OF 14120), Georgievskiy sand pit, 1960 excavations; Early Pleistocene, the beginning of the Late Villafranchian.

The study of teeth was carried out according to a standard methodology (Maglio 1973; Garutt and Foronova 1976). The definition of the generation of the tooth and the degree of its wear was made using the methods of Sher and Garutt (1985).

**Abbreviations:** AMZ – Azov Museum-Reserve, Azov, Russia; GIN – Geological Institute RAS, Moscow, Russia; ZIN – Zoological Institute RAS, Saint Petersburg, Russia; PKM – Pyatigorsk Local Museum, Pyatigorsk, Russia; SGMZ – Stavropol State Museum-Reserve, Stavropol, Russia.

## RESULTS

**Skull without tusk.** The skull with the mandible of *A. meridionalis meridionalis* is located in the exposition of the Pyatigorsk Local Museum (coll. PKM No. OF 4622) belongs to a large adult male with M3/m3 teeth of the fourth wear degree (Fig. 4). The skull is well preserved. The right tusk is developed normally, its length by a large curvature is about 280 cm, the thickness at the exit from the alveoli is 220 mm. A feature of this specimen is the complete absence of the left tusk, which was lost by the animal during life. The alveolar pocket is completely healed. There are no signs of an inflammatory process or trauma on the premaxillary bones. The redistribution of weight on the chewing surfaces of the teeth led to an oblique wearing of the tooth crowns. On the left teeth, the erasure angle reaches about 16°. Thus, the ventral-lingual slope of the masticatory surface on the lower m3 is 74°, and the dorso-buccal slant on the upper M3 is 106°.



**Fig. 4.** The skull of *Archidiskodon meridionalis meridionalis* from Georgievsk sand pit (collection PKM No. OF 4622), Stavropol Territory; Early Pleistocene, Late Villafranchian, front view.

**Pathology of upper teeth replacement.** The dental system a *A. meridionalis meridionalis* from the skeleton of the male from the exposition of the Stavropol Museum-Reserve (coll. SGMZ No. OF 14120) is at the stage of the replacement M2/m2 – M3/m3. The right tooth M3 developed correctly. The length of its crown is 256 mm, width – 104 mm, dental formula  $t12t$ , lamellar frequency at 10 cm – 4.5–5.0, enamel thickness – 3.6 mm. The average length of single plate


is 19.2 mm. The plates are parallel to each other. The coefficient of wearing of the crown is 5 (Fig. 5A). In the left half of the upper jaw, there is a strongly erased M2 and a significantly deformed M3. On the M2 tooth, there are 7 parallel plates and posterior talon with normal development of enamel, dentin and cement (Fig. 5G). Two posterior roots resorbed not completely, have a size of 9×9.5 mm and 10×11 mm. The M3 tooth has an anomalous structure (Fig. 5B, C). The aboral part of the tooth is relatively normal, its width reaches 109 mm; the average length of single plate is 19.6 mm. The wear stage of tooth – 5. Between the sixth and seventh plates, the fracture of the axis of the crown is observed – its front part is considerably shifted to the buccal side. The medial half of the anterior plates is wrapped at 136–137°, and the lateral half of the plates – at 40–42°. Thus, the central line of the rostral part of the crown is located at about 104° relatively to the main axis of the tooth. The total number of plates besides the anterior and posterior talons is 12, which corresponds to the nonabnormal right tooth. In this case, the main longitudinal axis M3 deviates aborally at 12°. And the lingual edge of M2 is slightly displaced medially relatively to the most lingual point of the M3 crown (Fig. 5A).

The presence of such anomaly on the upper teeth had a little effect at the functioning of the lower teeth. There is a replacement of m2 to m3 on the lower jaw from this skull. Significantly erased m2 consists of 6 plates and a posterior talon at the right and 5 plates at the left one. There is a slight deformation in the form of a crumpled posterior plate and talon at a slightly more wearing left m2. On the left m3 (the wear stage 2), the first five plates are erased somewhat more than at the right one. The anterior talon is under the aboral part of the previous tooth's crown (Fig. 6). There is a somewhat stronger erosion of cement on the buccal side of the crown of right m3 in the form of a wide shallow furrow.

## DISCUSSION

Cases of pathological changes at ancient elephants are rare. Therefore, the accumulation of data on their diseases is important for understanding the characteristics of their biology and interaction with the environment. The examples of deviations in the development of the dental system in southern elephants from the territory of the Ciscaucasia considered by us, indicate a lack of significant differences



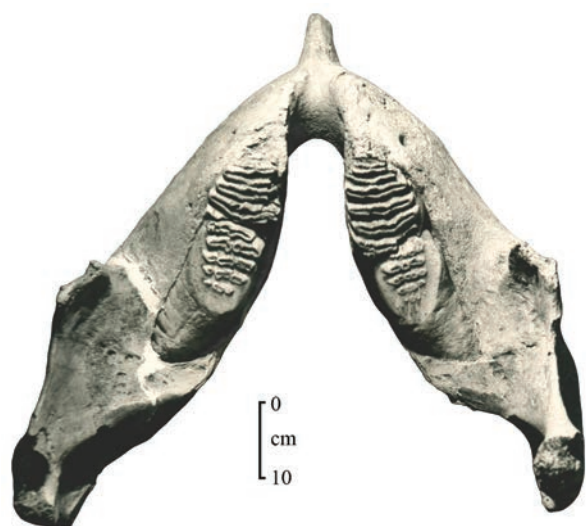


**Fig. 5.** The teeth of the upper jaw of *Archidiskodon meridionalis meridionalis* from Georgievsk sand pit (collection SGMZ No. OF 14120), Stavropol Territory; Early Pleistocene, Late Villafranchian: A – upper jaws with teeth M3 (right) and M2, M3 (left), view from below; B–C – abnormal left tooth M3, B – occlusal view, C – front view; D – left M2, buccal view.

from those of woolly mammoths and modern Asian and African elephants.

In the case of *A. meridionalis meridionalis* skull (coll. PKM No. OF 4622), we are probably dealing with the case of tusk loss already in the adult age,

when the alveoli and premaxillary bones were fully formed. Probably, the loss of one of the tusks was due to a serious injury or during a mating battle. Breaking off the tusk occurred inside the alveoli, which prevented its further growth and subsequently led



**Fig. 6.** The lower jaw of *Archidiskodon meridionalis meridionalis* from Georgievsk sand pit (collection SGMZ No. OF 14120), Stavropol Territory; Early Pleistocene, Late Villafranchian, view from above.

to its overgrowing. Such cases are described in modern *Loxodonta africana* Blumenbach, 1797 and *Elephas maximus* L., 1758. In India, such “one-tusk” elephants are called “ganesha”. In ordinary life, the absence of one of the tusks has little effect on the lifestyle of modern elephants. In the described case, the individual of the southern elephant, apparently, also functioned normally, and the existing pathology affected only slightly at the character of M3/m3 wearing.

A case of a disturbance of the M2 tooth replacement on M3 in one of the jaws was recorded at the skull of the southern elephant’s skeleton from Georgievskiy sand pit (coll. SGMZ No. 14120). The absence of such anomalies on the right upper dentition and on the teeth of the lower jaw may indicate a lack of genetic predispositions to such a pathology. There are no obvious traces of inflammation or trauma on the upper jaw, which allow us to reject the effect of influence of diseases or physical trauma on the problem of replacing the teeth in the individual being investigated. The obvious cause of this anomaly was a disorder of the growth rate of M3 and slowing the intensity of crown wear and resorption of the two posterior roots of M2. As a result, the lack of space in the alveolar pocket of the left M3 prevented the normal development and growth of the tooth of the last replacement. The alveolus of the normal M3 tooth

on the right side has a length of 245 mm, and the alveolus of the M3 tooth with a pathology – 159 mm. The change of the front six plate’s position and the talon occurred at the stage when these enamel plates were already formed, but weakly associated with the subsequent ones by cement. Probably, at this time the vector of resistance from M2 was not already directed along the axis of the M3 crown, and partially was displaced medially. Later, during the growth of M3, the mutual pressure led to an even larger displacement of the M2 crown in the lingual direction, and the medial half of the M3 enamel plates increasingly bent laterally. As a result, M3 turned out to be strongly deformed, and M2, partially displaced into the oral cavity, did not fall out, but remained functioning for a while, violating the food regime of the elephant. On the lower jaw, the posterior part of the m2 crowns continued to function, as it is known that the upper teeth are erased somewhat faster (Garutt 1977). The modified upper left molars caused a somewhat more intense wear of the plates of the lower m2 and m3. The possible pain sensations that arose during the process of chewing food forced the animal to modify somewhat the movements of the jaws. This led to a somewhat greater grinding of the buccal side of the right M3. The cause of such a disturbance was hardly a problem with nutrition, since all other teeth developed normally. In addition to dental pathology, the elephant has traces of destructive changes in bone tissue, similar to osteodystrophy development (Leshchinskiy 2017). Especially pronounced they are traced on the epiphyseal parts of large tubular bones, on the patellas, on the bones of the manus and pes (phalanges, metapodiums, heel bones, astragali) (Fig. 7). Similar cases of bone diseases are known in woolly mammoths (for example, in Leshchinskiy 2017). At the moment it is difficult to say what was the initial cause of such anomalies of the individual and his death – problems with nutrition due to dental pathology or disease of the musculoskeletal system.

Probable causes of the pathology of the dental system in the described cases are abnormality that occurred during the functioning of the teeth. But it is known that abnormalities in the development of the teeth described in the literature are marked as at one of the jaws or at the both. In addition, various anomalies of teeth in mammoths were noted simultaneously on the upper and lower teeth (Maschenko and Shpansky 2005). Therefore, most likely the reasons causing such changes can be caused by different





**Fig. 7.** Cases of osteodystrophy on the bones of the mounted skeleton of *Archidiskodon meridionalis meridionalis* from Georgievsk sand pit (collection SGMZ No. OF 14120), Stavropol Territory; Early Pleistocene, Late Villafranchian: A – distal part of left tibia, medial view; B – right patella, view from above; C – tarsal bones of the right foot, front view. Without the scale.

reasons or by their complex. Further accumulation of actual material will clarify this issue.

#### ACKNOWLEDGEMENTS

The authors are grateful to their colleagues from the Nature Department of the Stavropol Museum-Reserve for their moral support and practical help during our work with the article. Special thanks go to Zemfira Korkmazova, a research associate in the Museum's Fund Department, for editing and preparing photographs for publication. Invaluable help was rendered us by dentists candidates of medical sciences E.A. Burtseva, A.V. Zalenskaya and S.N. Krajan. They took interest in our research, critically evaluated the course of arguments about the dental diseases of elephants, thereby contributing to the exit from seemingly deadlock situations.

The work was carried out within the framework of the State task of the SSC RAS for 2018, project No. 0256-2018-0025 (State Registration No. 01201363186) (V.V. Titov).

#### REFERENCES

- Adam K.D.** 1994. Anomalien des Zahnwechsels bei *Elephas primigenius* aus dem Quartar des Oberrheins. *Stuttgarter Beitrage zur Naturkunde, serie B (Geologie und Palaontologie)*, **211**: 1–36.
- Aguirre E.E. and Morales J.** 1990. Villafranchian faunal record of Spain. *Quartärpaläontologie*, **8**: 7–11.
- Baygusheva V.S., Titov V.V. and Foronova I.V.** 2016. Teeth of early generations of elephant *Archidiskodon meridionalis tamanensis* (Mammalia, Elephantidae) from Sea of Azov Region (Russia). *Quaternary International*, **420**: 306–318.
- Burns J.A., Baker C.G. and Mol D.** 2003. An extraordinary woolly mammoth molar from Alberta, Canada. *Deinsea*, **9**: 77–85.
- Colyer N.** 1994. Colyer's Variations and diseases of the teeth of animals. Revised Edition. A.E.W. Miles and C. Grigson (Eds). Cambridge University Press, Cambridge, 672 p.
- Dubrovo I.A.** 1989. The systematic position of the Khaprovian elephant. *Paleontological Journal*, **1**: 78–87. [In Russian].
- Foronova I.V.** 1999. Quaternary mammals and stratigraphy of the Kuznetsk Basin (South-Western Siberia). *Antropozoikum "Quaternary of Siberia"*, **23**: 71–98.
- Garutt V.E.** 1954. Southern elephant *Archidiskodon meridionalis* (Nesti) from Pliocene of the Northern coast of the Sea of Azov. *Trudy Kommissii po Izucheniyu Chetvertichnogo Perioda*, **10**(2): 1–76. [In Russian].
- Garutt V.E.** 1977. Dental system of elephants in individual and phylogenetic development. *Trudy Zoologicheskogo Instituta Akademii Nauk SSSR*, **72**: 58–67. [In Russian].
- Garutt V.E. and Foronova I.V.** 1976. The study of teeth of extinct elephants: methodical recommendations. Institute of geology and geophysics SB AN SSSR, Novosibirsk, 36 p. [In Russian].
- Garutt V.E. and Safronov I.N.** 1965. A find of a skeleton of the southern elephant *Archidiskodon meridionalis* (Nesti) near the town of Georgievsk (Northern Caucasus). *Byulleten Kommissii po Izucheniyu Chetvertichnogo Perioda*, **30**: 79–88. [In Russian].
- Garutt W.E.** 1998. A skeleton of the southern elephant, *Archidiskodon meridionalis* (Nesti, 1825), from a sand pit near Georgievsk, Northern Caucasus, Russia. *Cranium*, **15**(1): 33–38.
- Gromov V.I.** 1977. Skull of elephant from Khapry. In: K.V. Nikiforova et al. (Eds). Paleontological basis of



- Anthropogene stratigraphy. Geological Institute RAS Press, Moscow: 83–94. [In Russian].
- Kirillova I. 2009.** Unusual tooth pathology in mammoth (*Mammuthus primigenius*) from Yakutia. *Russian Journal of Theriology*, **8**(1): 29–36.
- Kirillova I.V., Shidlovskiy F.K. and Titov V.V. 2012.** Kashtyktakh mammoth from Taimyr (Russia). *Quaternary International*, **276–277**: 269–277.
- Krzemińska A. 2008.** Preliminary characteristics of pathologies found in the skeletons of mammoths at the Kraków Spadzista street (b) site. *Veterinarija ir zootechnika*, **43**(65): 52–57.
- Kuzmina I.E. and Praslov N.D. 1992.** Anomalies in the structure of teeth and limb bones of mammoths from the Late Paleolithic site of Kostenki 1. *Trudy Zoologicheskogo Instituta Akademii Nauk SSSR*, **246**: 68–71. [In Russian].
- Lebedeva N.A. 1978.** Correlation of the Anthropogene strata of the Pontian–Caspian Sea. Nauka, Moscow, 136 p. [In Russian].
- Leshchinskiy S.V. 2017.** Strong evidence for dietary mineral imbalance as the cause of osteodystrophy in Late Glacial woolly mammoths at the Berelyokh site (Northern Yakutia, Russia). *Quaternary International*, **445**: 146–170.
- Lister A. and Bahn P. 2007.** Mammoths: giants of the Ice Age. Revised Edition. University of California Press, Berkeley, 192 p.
- Maglio V.J. 1973.** Origin and evolution of the Elephantidae. *Transactions of the American Philosophical Society, New Series*, **63**(3): 1–149.
- Maschenko E.N. 2002.** Individual development, biology and evolution of the woolly mammoth. *Cranium*, **19**(1): 1–120.
- Maschenko E.N. and Shpansky A.V. 2005.** Abnormal dental morphology in the mammoth *Mammuthus primigenius* Blumenbach, 1799. *Paleontological Journal*, **39**(1): 93–100.
- Maschenko E.N., Kondaurov A.A. and Sher A.V. 2008.** New data on the aberrant dentition of woolly mammoth (*Mammuthus primigenius*). Abstracts of 6th meeting of the European Association of vertebrate palaeontologists (30 June–5 July 2008, Spišská Nová Ves). Spišská Nová Ves: 66–68.
- Nikolaev V.I., Alexeev A.O., Maschenko E.N., Kuznetsova T.V. and Yakumin P. 2017.** Reasons of pathologies of Yakutian mammoths' tusks in the Late Pleistocene by data of isotopic and geochemical investigations. *Izvestiya Rossiiskoi Akademii Nauk. Seriya Geograficheskaya*, **1**: 99–105. [In Russian].
- Niven L. and Wojtal P. 2002.** Cement furrows in the dentition of *Mammuthus primigenius* and the question of their etiology. *Acta zoologica cracoviensia*, **45**(2): 307–319.
- Niven L. and Wojtal P. 2003.** Paleocological implications of tooth pathologies in *Mammuthus primigenius*: examples from Central Europe. Abstracts of 3rd International Mammoth Conference (24–29 May 2003, Yukon). Yukon: 118–119.
- Rossi M.A., Agostini S., Palombo M.R., Angelini I., Caramiello S., Casarin F., Ghezzi E., Marano F., Molin G., Reggiani P., Sangati C., Santello L., Socrate G. and Vinciguerra E. 2017.** *Mammuthus meridionalis* from Madonna della Strada (Scoppito, L'Aquila): diagnostics and restoration. *Bollettino della Società Paleontologica Italiana*, **56**(3): 359–373.
- Roth V.L. 1989.** Fabricational noise in elephant dentitions. *Paleobiology*, **15**(2): 165–179.
- Sher A.V. and Garutt V.E. 1985.** On the technique for the identification of molar generations in extinct elephants. *Trudy Zoologicheskogo Instituta Akademii Nauk SSSR*, **131**: 93–103. [In Russian].
- Shpansky A.V. 2014.** Variations in the teeth's morphology of a woolly mammoth *Mammuthus primigenius* (Blumenbach, 1799) (Mammalia: Elephantidae). *Trudy Zoologicheskogo Instituta Akademii Nauk RAN*, **318**(1): 24–33. [In Russian].
- Tesakov A.S. 2004.** Biostratigraphy of the Middle Pliocene – Eopleistocene of Eastern Europe. Nauka, Moscow, 247 p. [In Russian with English summary].
- Titov V.V. 2008.** Late Pliocene Large Mammals of the Northeastern Sea of Azov Region. YuNTs RAN, Rostov-on-Don, 264 p. [In Russian with English summary].
- Titov V.V. and Shvyreva A.K. 2016.** Deer of the genus *Megaloceros* (Mammalia, Cervidae) from the Early Pleistocene of Ciscaucasia. *Paleontological Journal*, **50**(1): 87–95.
- van Essen H. 2004.** A supernumerary tooth and an odontoma attributable to *Mammuthus primigenius* (Blumenbach, 1799) (Mammalia, Proboscidea) from The Netherlands, and various related finds. *Acta zoologica cracoviensia*, **47**(1–2): 81–121.
- Vereshchagin N.K. 1960.** Diseases of teeth of Yakutian mammoths. *Byulleten Komissii po Izucheniyu Chetvertichnogo Perioda*, **24**: 109–111. [In Russian].
- Vereshchagin N.K. 2002.** From muskrat to mammoth. Asterion Publishes, Saint Petersburg, 336 p. [In Russian].
- Wojtal P. 2001.** The woolly mammoth (*Mammuthus primigenius*) remains from the Upper Palaeolithic site Kraków Spadzista Street (B). Proceedings of the First International Congress: The World of Elephants (16–20 October, Rome). Rome: 367–372.